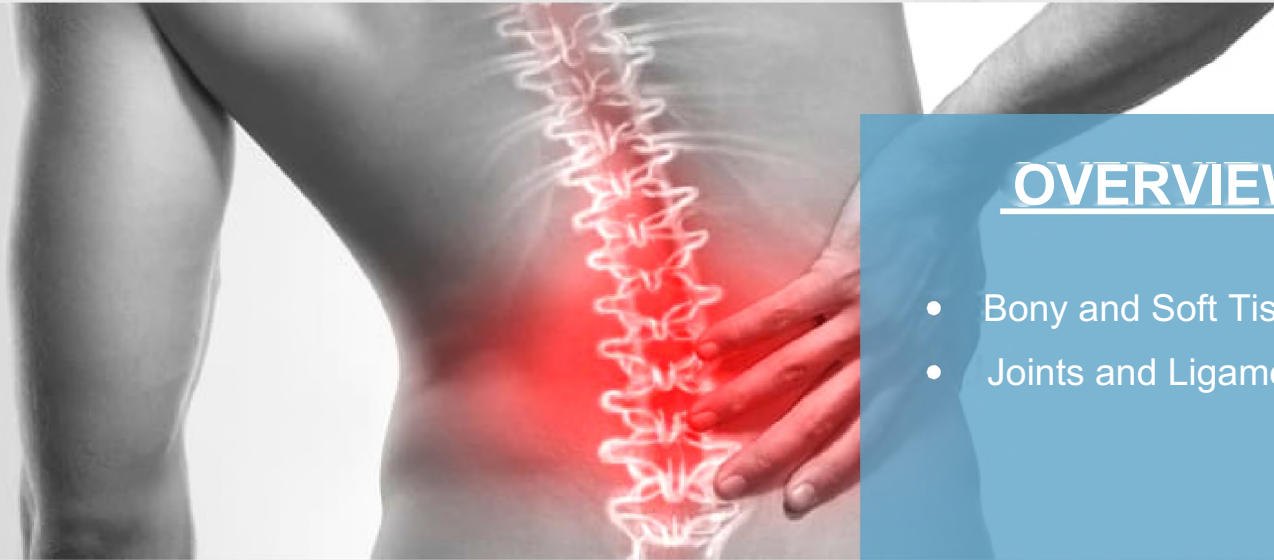


THE LOW BACK

LOWDOWN



OVERVIEW

- Bony and Soft Tissue
- Joints and Ligaments

Lumbar Spine Anatomy

Last month my colleague wrote the first of 5 articles in our Lowback Lowdown Series, discussing the lower back. In the article, she discussed how an athletic trainer could go about observing and evaluating a lower back injury/pain and told her own story along the way. During this series of articles, we hope to briefly illustrate how we as athletic trainers go about the observation, evaluation, and treatment of low back pain. In this, second article, I am going to provide the opportunity to learn about some of the anatomy and mechanics of the lumbar spine.

Brief Disclaimer

For those of you taking the time to read through this, we would like to be clear, this is most certainly not how undergraduate students learn about the anatomy and biomechanics of the lumbar spine. It takes a tremendous amount of time, studying, observation and practice to be able to break down the lumbar spine into just 5 articles. We hope to continue our lower back conversation in the future so let's get started.



Bony and Soft Tissue Anatomy

The Vertebrae

The lumbar spine itself is composed of 5 lumbar vertebrae, the sacrum, and the coccyx. This particular section of the vertebral column (spine) is designed to be stable, stiff, and supportive (3). The 5 lumbar vertebrae are the thickest vertebrae in the spine, we call these L1-L5. Please note the anatomy of lumbar vertebrae from **Diagram 1**. Structurally the vertebrae 'lock' or 'fit' together with the vertebrae above via inferior articular facets and superior articular processes creating a more stable environment as we go lower into the lumbar spine(2). The vertebrae are also responsible for protecting the spinal cord (housed in the vertebral arch) and the various levels of spinal nerves that exit through the intervertebral notches (on both the left and right sides of the body)

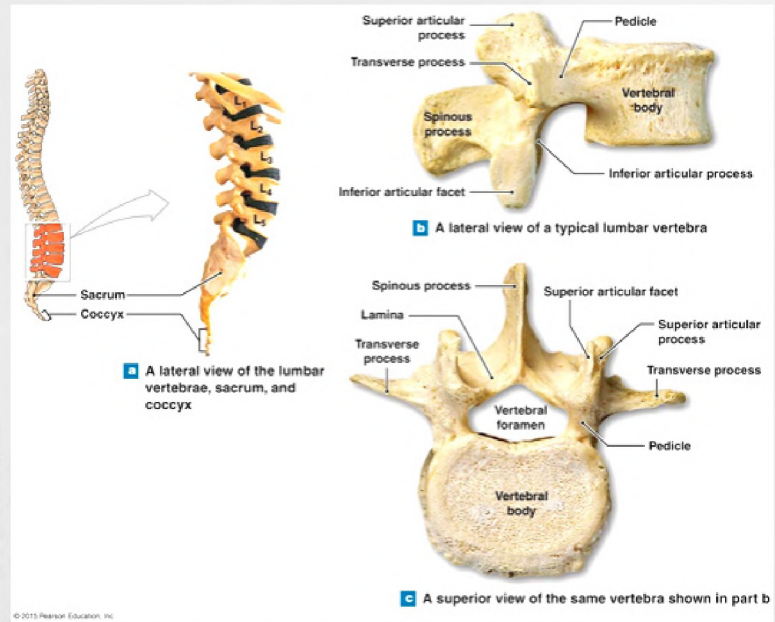


Diagram 1

The Sacrum and Coccyx

The sacrum is a bone located at the bottom of the spine. The sacrum connects between the two hip bones and L5 of the lumbar spine. Please note the anatomy of the sacrum in **Diagram 2**. The sacrum is a fusion of 5 bones (S1-S5) that houses an assortment of nerves that run through the protective sacral canal exiting from its foramina both in the front and the back on the left and right sides of the body respectively (4 ventral and 4 dorsal) (2). Finally, the coccyx or "tailbone" is a series of small bones (ranging from 3-5 bones) fused to the sacrum (3). Please note **Diagram 2**.

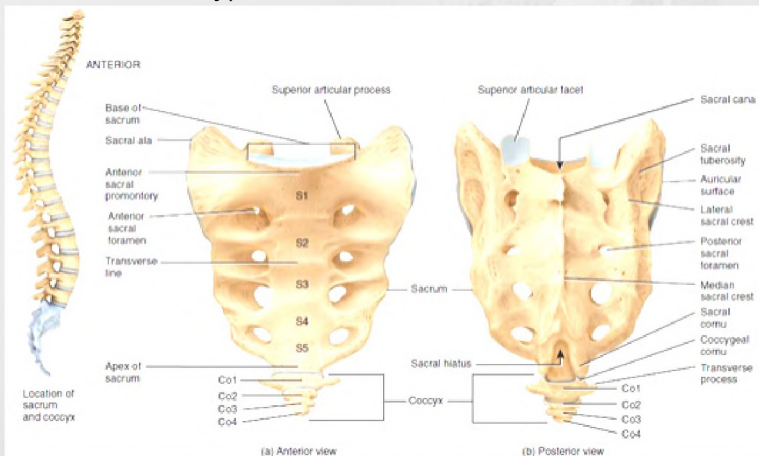


Diagram 2

The Intervertebral Discs

In between each vertebra (L1-L5) and L5 and the Sacrum (S1) are intervertebral discs. The intervertebral discs are made up of fibrous tissue called the annulus fibrosus and a jelly-like substance called the nucleus pulposus at its core. These discs act like springs between each vertebra (1). They provide a cushion and spring-like quality and allow small degrees of motion to the vertebrae especially when under external loads (1). Please note the anatomy of intervertebral discs in **Diagram 3**.

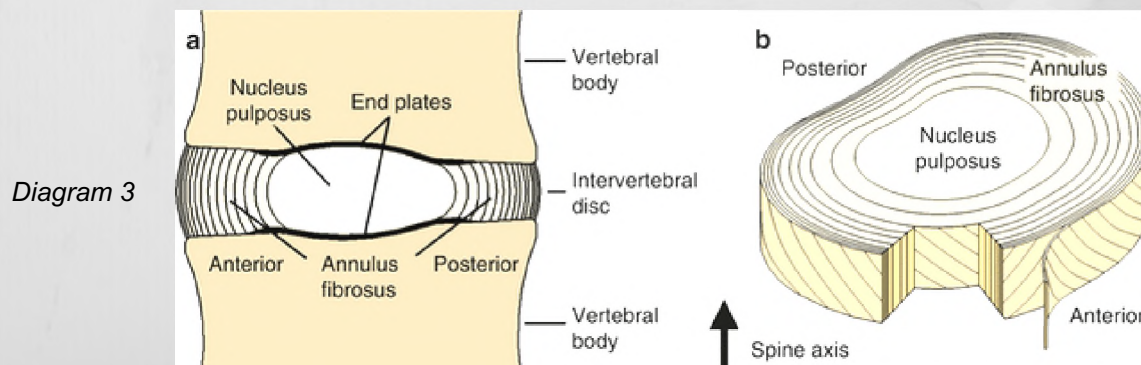


Diagram 3

Joints and Ligaments

Joints

There are 3 basic joints in the lumbar spine. They are the Facet Joints, Cartilaginous Joints, and finally, the Sacroiliac Joints. Each of these joints has a specific role to play in the lumbar spine. We will illustrate them briefly, but to find out more about these joints you will just have to read the third Lowback Lowdown article which discusses biomechanics in more detail.

The Facet joints are composed of the Inferior Facet of the vertebrae above articulating with the Superior Facet of the vertebrae below (3). These joints allow for flexion, extension, and hyperextension to occur between each vertebra (1). See **Diagram 4**

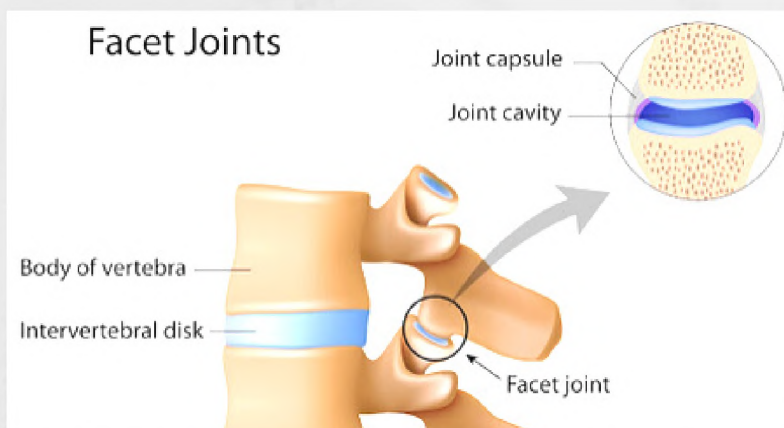


Diagram 4

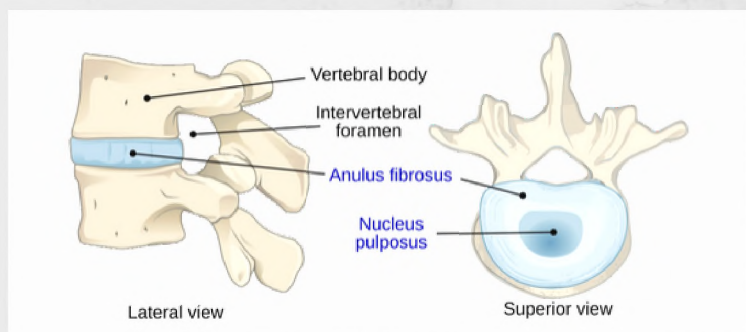


Diagram 5

The Sacroiliac joint comprises the Iliac Crests articulating with the Sacrum on both the left and right sides (4). Admittedly, this joint is weird. The primary function of this joint is to provide stability to the lumbar spine by transmitting force from the lower extremities (hips and legs). We will go into more detail about biomechanics in the second installment of lumbar spine anatomy. See **Diagram 6**

The Cartilaginous joints are formed by the intervertebral disc and the body of the vertebrae above and below it (2). These joints allow for flexion, extension, rotation, and hyperextension. These joints, due to the ability of the intervertebral disc to absorb shock and bodyweight, act like a spring to handle compressive forces and distribute them quite efficiently throughout the spine (1). See

Diagram 5

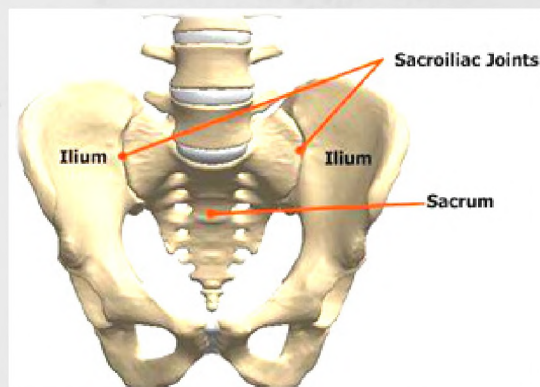


Diagram 6

Ligaments

These ligaments are made up of thick fibrous material and are found on the entire length of the spine (3). They are listed below in order anterior to posterior (beginning at the body and ending at the spinous process of the vertebrae) and are depicted in **Diagram 7** and listed below:

- Anterior Longitudinal Ligament (Red)
- Posterior Longitudinal Ligament (Purple)
- Ligamentum Flavum (Turquoise)
- Interspinous Ligament (Green)
- Supraspinous Ligament (Yellow)

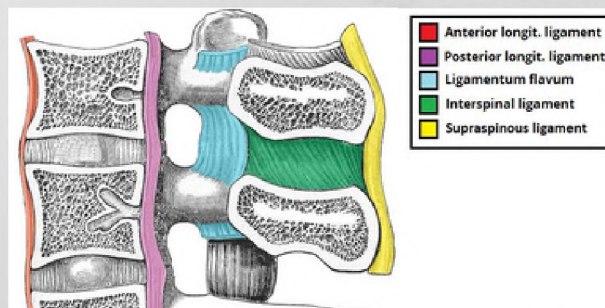


Diagram 7

Conclusion

I hope that by reading this brief overview you have achieved one of two things. One, you have learned something new. Two you are interested in reading the following article to learn about the musculature and biomechanics of the lumbar spine. I understand that anatomy can be boring, however it is extremely important for careers ranging from personal trainers to orthopedic surgeons. You will be referencing and reading numerous resources (like this one) to memorize, illustrate, and apply what you learned in that undergraduate lecture and lab course. I guarantee you will think to yourself “ I am never going to use this in the real world.” Well, eventually you will have a client or patient ask you a specific question (most likely one they googled) and expect you to explain what it is, why it's happening and what can be done about it on the spot. How do we stay fresh and avoid these awkward moments? Reading and practicing our crafts as much as possible!

In the next anatomy article, we will be illustrating the musculature and briefly explaining the basic biomechanics of the lumbar spine. We look forward to any questions you may have. You can email us at the addresses listed below. If you need any further assistance you can find us online at [RecWell Athletic Training](#) and schedule a clinic visit at Ritchie Coliseum or Telehealth visit.

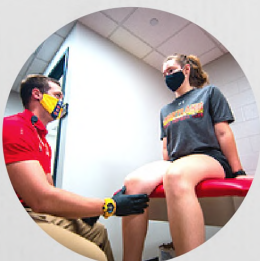References

Hall, S. J. (2007). Basic Biomechanics (5 ed.). New York: McGraw Hill. Retrieved 2021

Seeley, R., Stephens, T. D., & Tate, P. (2008). Anatomy & Physiology (8 ed.). New York: McGraw Hill. Retrieved 2021

Starkey, C., Brown, S. D., & Rayn, J. (2010). Examination of Orthopedic and Athletic Injuries (3 ed.). Philadelphia: F.A Davis Company. Retrieved 2021

Thompson, J. C. (2010). Netter's Concise Orthopaedic Anatomy (2 ed.). Philadelphia: Saunders Elsevier. Retrieved 2021



*Written By: Thomas L. Bennett,
MPSM, LAT, ATC, FMT, FMS, GT
Thomas is the Assistant Athletic Trainer for
the RecWell Athletic Training Program and
has been since the program's inception in
2018.*



Alysia Henderson
ahenderson@som.umaryland.edu

Thomas Bennett
thomasbennett@som.umaryland.edu